



<https://doi.org/10.15407/scine18.06.083>

GLUSHCHUK, M. I.¹ (<https://orcid.org/0000-0001-7723-6386>),
SHUSTAKOVA, G. V.¹ (<https://orcid.org/0000-0002-8737-0359>),
GORDIYENKO, E. Yu.¹ (<https://orcid.org/0000-0002-8692-8605>),
FOMENKO, Yu. V.¹ (<https://orcid.org/0000-0003-3108-8431>),
OLIYNYK, G. A.² (<https://orcid.org/0000-0002-7445-553X>),
DVORTCEVYI, V. V.² (<https://orcid.org/0000-0003-3632-9361>),
KREMEN, V. O.² (<https://orcid.org/0000-0002-2946-9430>),
KOVALOV, G. O.³ (<https://orcid.org/0000-0002-5714-6698>),
CHYZH, M. O.³ (<https://orcid.org/0000-0003-0085-296X>),
and SUPRUN, K. G.⁴ (<https://orcid.org/0000-0003-2540-9147>)

¹ B. Verkin Institute for Low Temperature Physics and Engineering of the National Academy of Sciences of Ukraine,
47, Nauky Ave., Kharkiv, 61103, Ukraine,
+380 57 340 2223, ilt@ilt.kharkov.ua

² Kharkiv Medical Academy of Postgraduate Education, Ministry of Health of Ukraine,
58, Amosova St., Kharkiv, 61176, Ukraine,
+380 57 711 3556, office@med.edu.ua

³ Institute for Problems of Cryobiology and Cryomedicine of the National Academy of Sciences of Ukraine,
23, Pereyaslavskaya St., Kharkiv, 61016, Ukraine,
+380 57 373 4143, cryo.ua@gmail.com

⁴ Institute of Dermatology and Venereology of the National Academy of Medical Sciences of Ukraine,
7/9, Chernyshevska St., Kharkiv, 61057, Ukraine,
+380 57 706 3200, idvnamnu@ukr.net

THERMAL IMAGING STUDY OF HUMAN SOFT TISSUE LESIONS AND BIOLOGICAL TISSUE EXPOSURE TO LOW TEMPERATURE *in vivo*

Introduction. *Infrared thermography has been currently used in clinical practice only as an additional method because of insufficient knowledge of the pathophysiological basis of thermal images.*

Problem Statement. *The main method for diagnosing the severity of soft tissue wound is a visual assessment by the doctor. As of today, there has been no non-invasive method for controlling the temperature dynamics in the frozen area under exposure to low temperature in real time.*

Purpose. *The purpose of this research is to evaluate the capabilities of thermography for the quantitative assessment of the severity of soft tissue wound in the case of thermal and other injuries, the non-invasive control of the state of the wound during treatment, the current control of the thermal field dynamics in the frozen area of the skin exposed to low-temperature effect.*

Citation: Glushchuk, M. I., Shustakova, G. V., Gordiyenko, E. Yu., Fomenko, Yu. V., Oliynyk, G. A., Dvortcevyi, V. V., Kremen, V. O., Kovalov, G. O., Chyzh, M. O., and Suprun, K. G. Thermal Imaging Study of Human Soft Tissue Lesions and Biological Tissue Exposure to Low Temperature *in vivo*. *Sci. innov.*, 18(6), 83–96. <https://doi.org/10.15407/scine18.06.083>

Material and Methods. Eighty patients with soft tissue lesions have been surveyed with the use of an original matrix thermal imager during the treatment. The soft tissues of 30 experimental animals exposed to low temperature has been controlled with the other original thermal imager designed to measure low-temperature thermal fields.

Results. A prognostic method for assessing the category of healing potential of burn wound based on the average relative temperature has been proposed. The ROC analysis (Receiver Operating Characteristic) has been used to assess the prognostic quality of the method: the numerical value of the area under the sensitivity and specificity curve of the method is 0.79, which corresponds to a good quality of the prognostic method. It has been found that the ratio of primary necrosis area diameter to that of frozen area is 0.63 ± 0.3 , at the used parameters of low-temperature impact. During the thawing, a long quasi-stable stage of the sizes and temperatures of the frozen area has been observed.

Conclusions. The thermography method has been established to be successfully used both for the monitoring of soft tissue lesions at all treatment stages, including the quantitative assessment of the healing potential of burn wounds and for the intraoperative control of the frozen area parameters during tissue cryo-destruction.

Keywords: thermography, soft tissues, burns, frostbite, and exposure to low temperature.

Infrared thermography (IRT) has been increasingly used in various fields of activity [1], thanks to the informativeness of the method itself and modern thermographs. They are compact, mobile, easy to use and have good parameters: high temperature sensitivity (hundredths of a degree), high spatial resolution (parts of a milliradian), and high frame rate (tens of hertz). These parameters make it possible to estimate the temperature field dynamics of various objects, particularly biological ones, with a high accuracy. The spectral sensitivity of most thermographs ranges within 3–5 μm and 8–14 μm , in which they see practically only surface temperature fields. However, these fields contain information about internal exothermic processes. The medical application of IRT is particularly attractive due to the non-invasiveness and functionality of the method itself, as well as the simplicity and cheapness of survey [2, 3]. IRT can be used for the diagnosis of many diseases, including for the initial assessment of the severity of soft tissue damage, detection of areas of necrosis, disorders of blood and lymph circulation, inflammation and other general pathological processes not always detectable by other clinical imaging methods. However, until now IRT has been used in practical medicine only as an additional survey method. The reason is that the pathophysiological fundamentals of thermal images have been understudied and, consequently, there have been no clinical protocols for thermographic survey. Thus, new data on the parameters

of the human skin thermal field contribute to the wider use of thermography in medical practice.

Soft tissue lesions may have various causes (wounds of various genesis, skin diseases), but thermal injuries (burns and frostbite) have the greatest social significance. The choice of treatment depends on how correctly the severity of thermal injury is assessed in the first hours after receiving it. First of all, it is a choice between conservative therapy and surgery. Untimely or inadequate treatment may lead to serious consequences such as disability or death either.

Burns are tissue wound caused by an increase in the temperature of the tissue to the level of cell death (44–51 °C)[4]. According to WHO estimates, 180,000 people die from burns every year. Burns vary in severity, depending on the depth, area, and location of the burn. Currently, Ukraine uses the following classification of burn wounds according to the depth of the wound [5]: I: superficial (heals within 3–7 days); IIa: partially superficial (heals within 1–3 weeks); IIb: partially deep (heals within 3–6 weeks with the formation of scars); III: deep (the wound does not heal without treatment, requires a skin transplantation). Doctors assess the severity of a burn wound based on visual and tactile characteristics of the wound, but the accuracy of such a clinical assessment varies from 50 to 70%, depending on the doctor's experience [6]. The heterogeneity of burn wounds further complicates this assessment. Therefore, a non-invasive objective method is

needed to provide early and accurate assessment of burn wounds.

There have been more than 10 different methods of analysis to assess the depth of a burn wound (or healing potential), including laser Doppler imaging (LDI), thermography, photoacoustic imaging, spectrophotometric intradermal analysis, dermatoscopy, ultrasound, and others [7]. The research authors have concluded that LDI is currently the most accurate method for assessing the depth of a burn wound; thermography is the second one. However, the LDI scanner is rather expensive, requires long-term fixation of the patient in one position, and can be used only 48 hours after the burn. These disadvantages limit its use in burn treatment centers.

Our previous studies have shown that IRT has good prospects for detecting pathological processes in the skin and underlying tissues [3, 8]. An important task of this research is to assess the capabilities of IRT for early (in the acute period of burn wound) diagnosis of the depth of the burn wound, as well as for the further control of the blood circulation and metabolic processes in soft tissues during the treatment of burn wound.

Frostbite (local cold injury) is tissue wound caused by local hypothermia. The severity of the wound depends on the duration and final temperature of tissue cooling. As a rule, there are 4 stages of frostbite, depending on the wound depth. The I and II stages are characterized by superficial frostbite, while the III and IV ones are deep [4]. Important periods in the pathogenesis of frostbite are the pre-reactive period (before tissue warming and blood circulation recovery), the early reactive period (within 24 hours from the moment of tissue warming), and the late reactive period (from the 2nd to the 15th day). Timeliness and adequacy of medical care is important for frostbite, because the pathological processes in cells and tissues at the early stages are characterized by high reversibility. Special attention is paid to the prognosis of the degree of frostbite in the pre-reactive and early reactive periods, as the results of this prognosis determine further treat-

ment [9]. Various possible types of diagnostic imaging, including angiography (contrast study of vessels with the use of CT, MRI) and LDI, are rarely used in clinical practice because of methodological difficulties and high cost.

One of the criteria for prognosticating the depth of tissue lesion in the early reactive period is skin temperature. In the case of superficial lesions (I–II), it remains normal or reduced by several Celsius degrees, but sharply decreases to room temperature in the case of deep lesions (III–IV) [10]. IRT is able to provide a simple and cheap non-invasive method for predicting tissue viability, especially in deep frostbite (III–IV). In the reactive period, there may arise septic complications of the wound process. They can be detected by thermography as an increase in the skin temperature. However, the main method of diagnosis is a subjective assessment of the severity of cold injury, based on the doctor's individual experience.

In the case of mechanical injury of soft tissues, inflammation plays a leading role in the course of the wound process; it is characterized by corresponding local signs, first of all, hyperemia (redness) and edema (swelling).

The expression and dynamics of these signs depend on the nature and extent of tissue wound, the type of infection, the general condition of the human body, as well as on environmental conditions. The evaluation of wound process indicators is largely subjective, except for skin temperature and hemogram (Common Blood Test). Therefore, IRT is one of the objective methods for monitoring wound healing. This method makes it possible to assess vascular reactions, activation of metabolic processes in the wound area. This is one of the most effective methods for dynamically controlling the inflammatory process in the wound. Thus, IRT can also be used to monitor mechanical wound healing.

Unlike the mechanical and thermal injuries, which have a precise date of occurrence, the wounds caused by skin and soft tissue infections (STIs) develop gradually; some of them do not heal for years. STIs can cause abscesses, ulcers, etc. It is very

difficult to objectively assess the activity of local manifestations of the infectious process. For this, only limited primary endpoints (criteria) are used: visual assessment of the degree of skin lesion in a certain area, lack of progression in the size of the affected area, indirect clinical signs of infection, biochemical and hematological markers. Research [11] has presented the results of measuring the dynamics of the infected limb skin temperature. The authors have noted the important role of skin temperature in the diagnosis and treatment of STIs.

Remote non-invasive IRT is also promising for monitoring the process of controlled decay of pathological tissue caused by exposure to low temperature (cryo-destruction). Cryo-destruction is used in dermatosurgery for the treatment of benign and malignant neoplasms, as well as other dermatological diseases [12]. The amount of destroyed tissues depends on the size of the frozen area, the temperature level reached in it, the duration of cooling and the rate of freezing/warming processes [13, 14]. To avoid tumor recurrence, surgeons excessively enlarge the area of cryo-destruction, including healthy surrounding tissue. Therefore, it is important to monitor the size dynamics of both the entire frozen area and the area of primary necrosis (irreversible damage to pathological tissues) in real intra operative time. Since the limit temperature of the necrosis area is different for different tissue types, it is necessary to control the temperature distribution in the frozen area. Ultrasound survey and CT allow estimating only the size of the frozen area, not the temperature in it. The promising method of MRI thermometry enables measuring internal thermal fields by analyzing the temperature dependence of some MRI parameters. However, the listed imaging methods are difficult to use directly in the course of cryosurgery. In addition, these methods have a number of significant methodological and economic limitations, especially in the conditions of small medical institutions. Hollow needles with thermocouples, which are commonly used in cryosurgery, enable measuring only individual points of the temperature field. In addition, the needle

insertion procedure is invasive and has limitations because of the risk of tumor cell dissemination. Therefore, the purpose of our research is to evaluate the possibilities and limitations of IRT for controlling skin cryo-destruction *in vivo*.

The research has been carried out by the IRT method in two directions.

The first direction (thermography of damaged soft tissues): 80 adult patients aged from 20 to 90 years old (30% women and 70% men), including 43 patients with burns, 12 with frostbite, 6 with mechanical injuries of soft tissues, and 19 with soft tissue wounds caused by infectious and other diseases were involved in the study. The largest group consisted of the patients with burns of various degrees, areas, and locations. In this group, 24 patients got flame burns (56%), 15 ones suffered from boiling water (35%), 2 patients were burnt by semi-liquid substance (molten bitumen and boiling porridge), one patient had a contact burn, and one got a radiation burn. In order to ensure the confidentiality of patient information, we provided each patient with an appropriate code under which all medical and thermographic information was processed. Whenever possible, each patient underwent a thermographic survey before the start of treatment (baseline session) and several times during the course of treatment.

Thermographic survey of patients is made with an original thermal field analyzer based on an uncooled matrix (384×288) of microbolometers [16]. A relative temperature scale is used for the quantitative analysis of the obtained thermograms. With this approach, the temperature in the area of interest T_{ai} is compared with the that of the selected reference (healthy) area T_{ref} [17]. Whenever possible, we use the thermal symmetry violation criterion, according to which the reference area is chosen as symmetrical and identical in terms of the area and shape to the area of interest. However, many patients with thermal trauma had damages of both limbs, or too large areas of the wound, which made it difficult to use the criterion of thermal asymmetry. In these cases, we choose a reference area in healthy tissues

near the wound, but no closer than 3 cm from the border of inflammatory process.

At the basic thermographic session, the relative temperature ΔT_0 of the wound surface is determined $\Delta T_0 = T_{ai} - T_{ref}$. This parameter is the main indicator for diagnosing the degree of the wound, and its dynamics reflect the wound condition in the course of treatment.

The black body model with a surface emissivity of 0.98 (like human skin) is used as an additional source of reference temperature, to control the radiant temperature of the room when estimating the depth of a thermal wound. To analyze the thermal field dynamics in the course of treatment, the exact location and size of the area of interest and the reference area selected for each patient in the baseline thermographic session are recorded in each subsequent session, if possible.

For the largest group of patients (with burn wounds), the research results have been evaluated with the use of statistical methods [18, 19]. ROC analysis (Receiver Operating Characteristic) that allows evaluating the prognostic value and quality of the diagnostic model has been used.

The second direction (the cryo-destruction of soft tissues), the dynamics of low-temperature thermal fields of the skin have been studied on 6-month-old white male rats (30 animals) in compliance with the requirements of the Bioethical Committee the Institute for Problems of Cryobiology and Cryomedicine of the NAS of Ukraine, based on [20]. A contact cryo-probe (cryo-applicator) actively cooled by liquid nitrogen has been used for studying low-temperature effect. The exposure to low temperature lasts 0.5 min (10 animals), 1 min (10 animals), and 2 min (10 animals) [21].

For this line of research, the original IR camera developed at B. Verkin Institute for Low Temperature Physics and Engineering of the NAS of Ukraine has been employed. The camera is built according to the principle of “open architecture” in accordance with the concept proposed in [22]. The modular design of hardware and software allows the adaptation of the camera to a specific task. The camera has a single-element, cooled de-

tor. The range of measured negative temperatures has been extended to $-190\text{ }^\circ\text{C}$. For this purpose, a reference emitter with a radiation temperature of approximately 78 K (the boiling temperature of liquid nitrogen) is included in the optical scheme of the device, which made it possible to significantly increase the accuracy of low-temperature measurements. The camera software has also been optimized for this task. For example, the function of automatically recording a half-hour “thermographic movie” has been added to track rapid changes in the temperature field. The “movie” is a sequence of digital thermal images with an interval of 1.5 seconds.

The thermal data have been processed by the method of primary statistical analysis and evaluated according to the Kruskal-Wallis test ($p < 0.05$) [23].

THERMAL FIELD STUDY IN THE CASE OF A THERMAL WOUND

The main task of the burn studies is the assessment of the capabilities and limitations of the IRT for the early prognosis of the wound depth (burn severity or healing potential). The depth assessment is based on the criteria prescribed by [6, 7].

The thermal data of 25 burn wounds of 18 patients surveyed by the IRT method in the first three days after the injuries have been processed by statistical methods. To assess the prognostic value and the quality of the diagnostic model, the ROC-analysis has been employed. The relative temperature ΔT_0 is estimated in the equal areas of interest of various wounds. ΔT_0 is compared with the corresponding depth of the wound, which is determined by the physician at the initial examination of the wound (clinical assessment) and with the final result (after 3–5 days after the injury). The obtained data are structured according to the three categories of clinical assessment of the wound depth:

“1” the wound heals without surgical treatment own within $\tau < 14$ days (\approx I–II degree);

“2” the wound may heal without surgical treatment within $14 < \tau < 21$ days (\approx IIa–IIb degree),

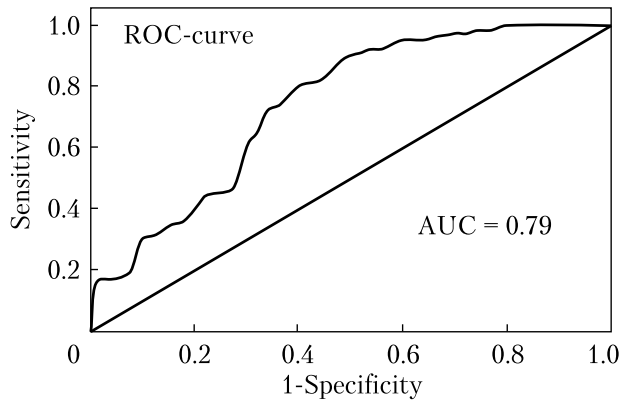


Fig. 1. ROC curve of sensitivity and specificity of the prognostic method

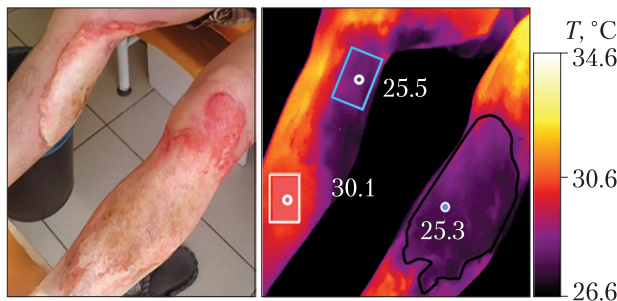


Fig. 2. Thermographic assessment of burn wound healing potential. The third day after a 5% flame burn, III degree

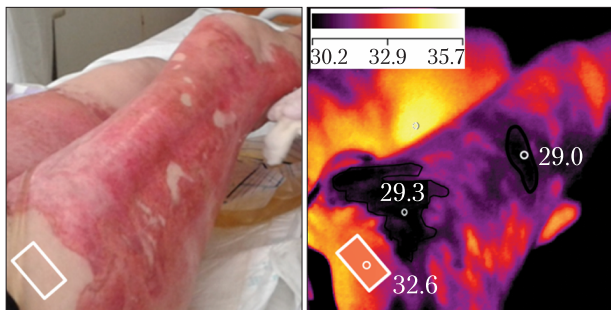


Fig. 3. Thermographic assessment of burn wound healing potential. The second day after a boiling water burn 20/10%, IIb–III degree

however, complications (scars) may arise. Therefore, the wound requires additional examination to make a decision about the necessity of plastic surgery (autodermoplasty);

“3” the wound cannot heal without surgical treatment or healing takes $\tau > 21$ days, with the

formation of hypertrophic scars and other complications. Therefore, plastic surgery (III degree) is necessary.

As a result of the analysis of structured data, it has been established that the mean values of $(\Delta T_0)_i$ have significant differences for each category of the clinical assessment of healing potential: $(\Delta T_0)_1 = +0.97$ °C, for category “1”, $(\Delta T_0)_2 = -0.74$ °C, for category “2”, and $(\Delta T_0)_3 = -2.5$ °C, for category “3”. Based on this, we have formulated a hypothesis about a significant difference in the mean value $(\Delta T_0)_i$ for different categories of lesion depth. The hypothesis of a reliable difference in the mean values has been confirmed based on the results of the analysis of variance of our data.

The further analysis aims at confirming the existence of a relationship between the mean values $(\Delta T_0)_i$ of burn wounds for each category and clinical assessments of the wound degree. Based on the categorical nature of the clinical assessment data, the method of non-parametric correlation analysis has been employed and the Spearman rank correlation coefficient has been calculated. As a result, a fairly significant positive correlation has been found between ΔT_0 and the clinical assessment (Spearman’s coefficient $r = 0.72$; $P < 0.001$). On the basis of the obtained data of statistical analysis, a method for assessing the category of the wound depth by ΔT_0 of a burn wound has been proposed:

- $(\Delta T_0) \geq 0$ °C: the relative temperature in the area of interest of the burn wound indicates category “1” of the wound depth;
- 0 °C $> (\Delta T_0) > -2.5$ °C: indicates category “2” of the wound depth;
- $(\Delta T_0) \leq -2.5$ °C: indicates category “3” of the wound depth.

So, as a result of the quantitative and statistical analysis of 25 burn wounds, the burn wound cutoff temperature [6] has been obtained $\Delta T_{co} = -2.5$ °C. If the cutoff temperature is below this value, autodermoplasty is required.

To assess the prognostic value and quality of the proposed method, the ROC analysis has been employed: the ROC curve of sensitivity and spe-

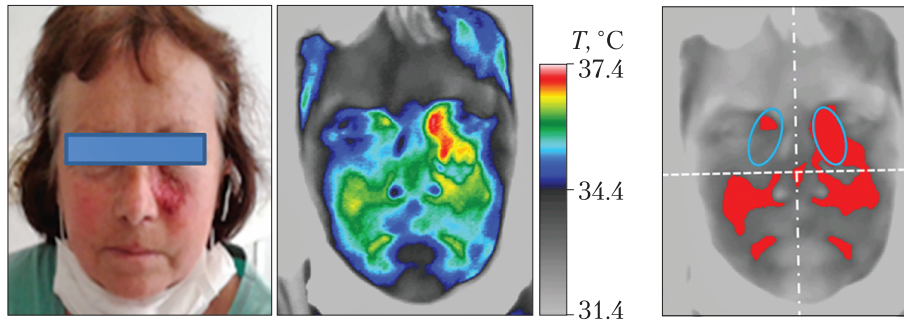


Fig. 4. Thermographic monitoring of burn wound dynamics. A patient with radiation dermatitis. From left to right: photo of radiation burn and two thermograms in different palettes. On the black-and-white thermogram, the areas with a temperature above $36\text{ }^{\circ}\text{C}$ are highlighted in red. The area of interest and the reference area are marked with blue ovals

cificity of the method is constructed and the area under it is calculated. The numerical value of the area under the curve ($\text{AUC} = 0.79$) corresponds to a high quality of the prognostic method (Fig. 1).

The results of thermographic survey of patients with burns of limbs in the acute period are presented in Figs. 2 and 3. Because of both limbs being burnt, the reference areas are chosen on the lower leg (Fig. 2) and on the thigh (Fig. 3), 3 cm from the edges of the inflammation (white rectangles on the thermograms). The mean temperature of the reference are a $T_{\text{ref}} \approx 29.9\text{ }^{\circ}\text{C}$ (Fig. 1). According to the proposed prognostic method and the obtained limit temperature, all areas of burns with temperature $T \leq T_{\text{ref}} - |\Delta T_{\text{co}}| = 30.1\text{ }^{\circ}\text{C} - 2.5\text{ }^{\circ}\text{C} = 27.6\text{ }^{\circ}\text{C}$ are referred to category “3” and require autodermoplasty. For visibility, such areas are outlined in black on the left lower leg. The other areas of the burn wound can heal without surgical treatment within 21 days, without the formation of rough scars. The assessment of the depth of the lesion (IIb–III stage) by the IRT method coincides with the clinical assessment (III stage). At the same time, IRT shows the exact shape and size of the areas referred to stage III.

The mosaic thermal field of a burn wound caused by boiling water splashes can be seen on the thermogram (Fig. 3). Within one large wound, there are scattered areas with varying severity of injury and, accordingly, with different healing

potential. The reference area of intact skin, which is selected in the upper part of the right thigh (white rectangle in the photo and thermogram), has an average temperature $T_{\text{ref}} = 32.6\text{ }^{\circ}\text{C}$. The black areas on the thermogram have a relative temperature equal to or below the limit temperature ($\Delta T_{\text{co}} = -2.5\text{ }^{\circ}\text{C}$). These areas require surgical intervention (autodermoplasty).

Also, an important task of the research is to evaluate the capabilities of IRT to control the dynamics of the wound process, including the assessment of the state of blood circulation and inflammatory processes in injured tissues at the stages of restorative treatment of burn wounds. Figure 4 features an example of processing a thermogram according to the criterion of thermal symmetry violation in order to quantitatively assess the dynamics of the state of a non-healing burn wound caused by radiation therapy 8 months ago. On the black-and-white thermogram, areas with a temperature above $36\text{ }^{\circ}\text{C}$ are highlighted in red. The area of interest and the reference area are marked with blue ovals. Both thermograms confirm the presence of thermal asymmetry only in the upper part of the face. The relative temperature of the area of interest (the temperature difference of the ovals) is $\Delta T = 1.2\text{ }^{\circ}\text{C}$. It should be noted that the hyperthermia area on the thermograms differs in shape and location from the visual area of the wound (see photo). The tem-

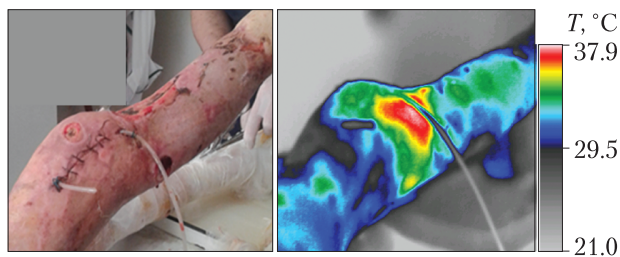


Fig. 5. Thermographic monitoring of complications during burn treatment. The photo and thermogram correspond to 15 weeks after a 50/40% flame burn, IIb–III degree. Purulent inflammation of the right knee joint. The joint is washed and drained




Fig. 6. Thermal picture of the feet of a patient with frostbite of the fingers in the early reactive period

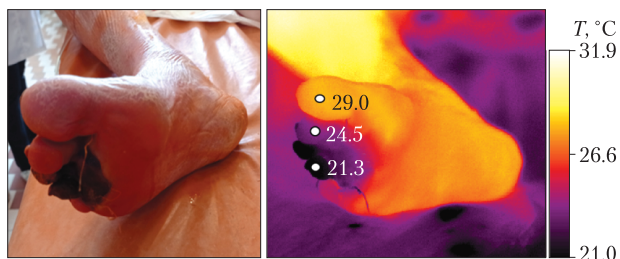


Fig. 7. Frostbite of three toes of the right foot during the reactive period

perature of the hyperthermic area in the healthy eye of 36.4 °C corresponds to the criteria of a healthy person [24].

Figure 5 shows an example of the detection and subsequent control of complications in the treatment of burn wounds, by the IRT method, namely, the detection of purulent inflammation of the knee joint and the control of the effectiveness of its treatment (wash with drainage). The thermogram

features an area of hyperthermia $\Delta T \approx 3.2$ °C caused by the purulent inflammation of the joint.

The thermographic survey of patients with frostbite aims both at diagnosing the stage of frostbite in the early reactive period and at monitoring the wound process in the late reactive period and in the period of granulation, epithelization, and scarring. Because of the fact that only a few patients underwent thermography in the early reactive period, no statistical analysis of thermal data has been made. However, the obtained data have indicated the effectiveness of using IRT to prognosticate the severity of injury based on the temperature of the frozen area surface.

The thermal pattern of the patient's frostbitten toes in the early reactive period (the first day) is presented in Fig. 6. The temperature of the toes (≈ 20 °C) does not exceed the ambient temperature, which indicates a deep frostbite of the toes (III–IV stage). The thermographic assessment is confirmed by the clinical examination, as well as the further course of the wound process.

Of the 12 patients with local cold injury, who were involved in the study, the majority was socially disadvantaged men aged from 42 to 60 years old with deep frostbite (III–IV stage) they got before the beginning of our study. Figure 7 presents the results of a thermal imaging survey of a local cold injury in the reactive period. The photo shows necrosis (blackening) of the 3rd and 4th toes, which is confirmed by the thermogram: the temperature of these toes does not exceed the ambient temperature. However, the thermogram also features an invisible in the photoviolation of the blood circulation of the 2nd toe, the temperature of which is 4.5 °C lower than that of the skin of the 1st (healthy) toe.

Multiple thermographic surveys of patients with frostbite in the late reactive period and in the period of granulation, epithelization, and scarring have also indicated the possibility of successful use of IRT for non-invasive monitoring of complications of the wound process.

Figure 8 presents an example of thermographic monitoring of complications that may occur dur-

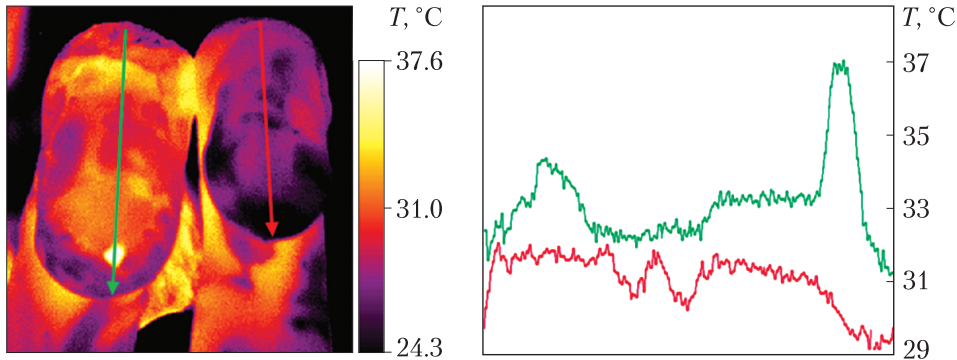


Fig. 8. Thermal imaging control of complications in the period of granulation, epithelization, and scarring. A patient with lower limbs amputated because of deep frostbite. IRT has shown an inflammatory process in the right stump

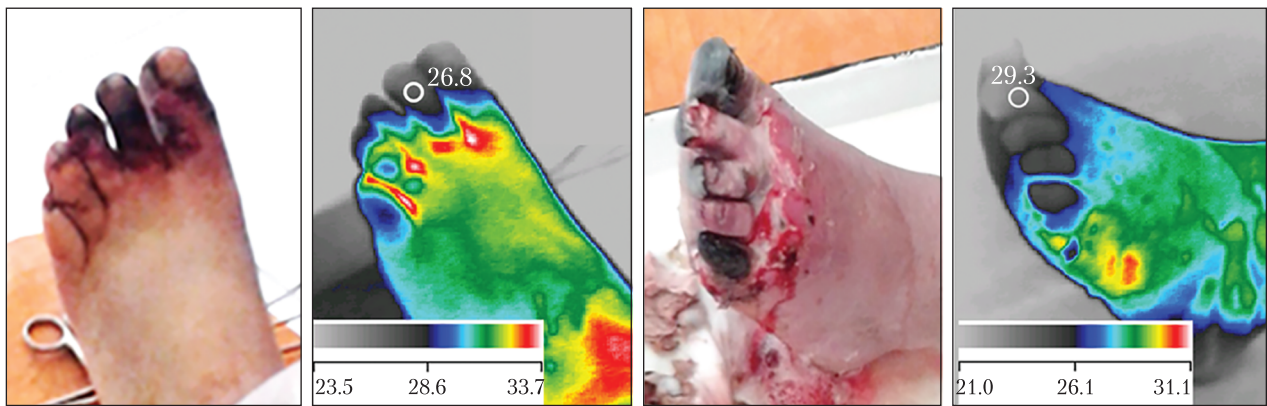


Fig. 9. An example of IRT capabilities. Photo/thermogram on the left: a patient with a toe wound caused by a mechanical injury; photo/thermogram on the right: a patient with gangrene of the toes caused by frostbite of the III stage

ing the granulation-scarring period in patients with limbs amputated because of deep frostbite. The thermogram shows the patient's stumps 5 weeks after the amputation. Both the thermogram and the thermal profiles along both stumps have indicated the development of inflammatory process in the right stump. As a result, the patient is scheduled for repeated amputation of a part of the right stump.

STUDYING THERMAL FIELDS IN WOUNDS OF OTHER ORIGIN

We have conducted thermographic surveys of soft tissue lesions caused by mechanical impact

and infectious or other diseases. The task of this research direction is to analyze the capabilities of IRT for the monitoring of the healing of mechanical wounds and for the objective assessment of the severity of wounds caused by soft tissue infection (STI) and their response to treatment.

Two pairs of photos/thermograms of the feet of two different patients are shown in Fig. 9. On the left, there is an injury to the toes from a mechanical impact, on the right, there is a picture of frostbite of the toes (III stage). Both injuries were received 10 days ago. The blackening of the fingers is visible in both photos. However, IRT features a significant difference in the temperature of the affected areas. The left thermogram shows that

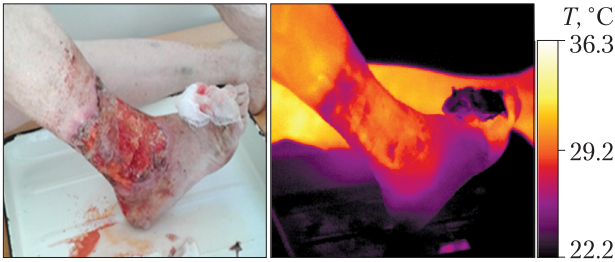


Fig. 10. A patient with a lower leg trophic ulcer caused by diabetes

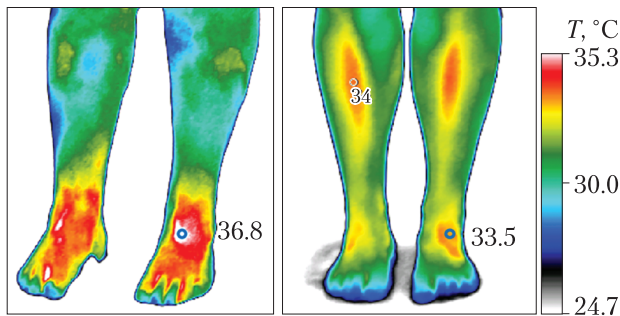


Fig. 11. Thermal image of the lower legs of a patient with foot mycosis and palmoplantar psoriasis (left) and of a healthy person (right)

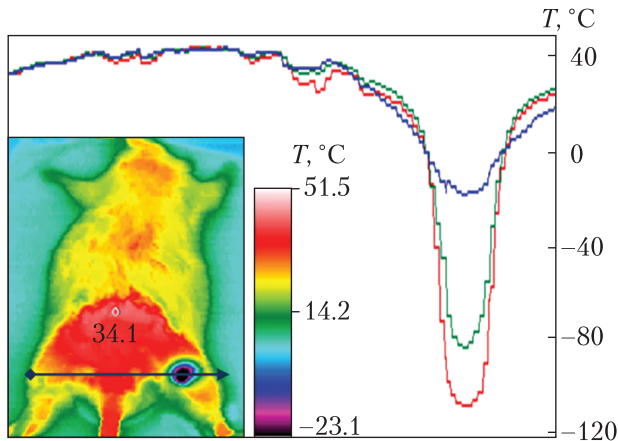


Fig. 12. Thawing of the frozen area after cryo-exposure lasting 0.5 min. Temperature profiles through the center of the frozen area in 2 s (red curve), 5 s (green), and in 90 s (blue) after the end of cryo-exposure. The inset shows a thermogram of a biological object (rat) at one of the moments of the quasi-stable stage. The arrow indicates the position of the temperature profile

the temperature of the toes is (6–7) °C higher than the ambient temperature even in the area of blackening, which is within the normal range for healthy toes of an adult. At the same time, in another patient, the temperature of the toes (see the thermogram on the right) does not exceed the ambient temperature, which is a sign of necrosis (gangrene) of any genesis. Thus, the causes of blackening of the skin can be differentiated by the temperature of the affected area:

- ◆ whether it arose from mechanical impact that results in an injury of the superficial vascular plexus, with microcirculation in the tissues remaining unaffected, which ensures heat flow to the surface of the skin in the affected area;
- ◆ whether it is caused by gangrene (tissue necrosis to a considerable depth).

Figure 10 features a pair of photos/thermograms of the right lower leg of a patient with a trophic ulcer caused by diabetes. The skin of the leg around the trophic ulcer is significantly colder (by almost 4 °C) than the similar areas of the healthy leg (in the background), which indicates impaired blood circulation.

Figure 11, on the left, shows a thermogram of the lower legs and feet of a patient with foot mycosis and palmoplantar psoriasis. There are areas of hyperthermia on both feet and lower legs. The temperatures of these areas exceed the temperatures of similar areas of a healthy person ($\Delta T \approx 3$ °C). For comparison, the thermal image of the lower legs of a healthy person is shown on the right.

STUDYING THERMAL FIELDS OF THE SKIN EXPOSED TO LOW TEMPERATURE

Also, using the IRT method, we have monitored in real time the parameters of the freezing and thawing areas caused by exposure to low temperature *in vivo* [21, 25]. The *in vitro* results [26] have demonstrated the hemispherical shape of the frozen volume under a point cryo-applicator. Based on this, we have assumed the equivalence of the radial temperature distribution on the surface and in the volume of the ice hemisphere.

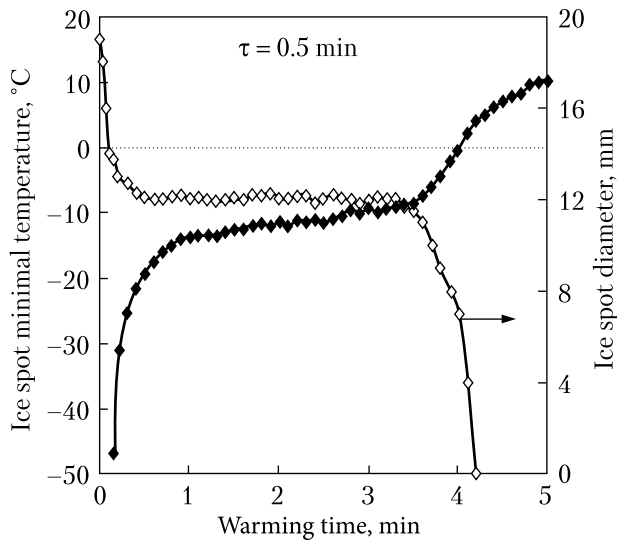


Fig. 13. Dynamics of the size of the ice spot and its minimum temperature during the thawing process

According to this approach, the dynamics of the thermal field in the ice spot on the surface reflects the dynamics of the temperature distribution in the volume of the ice hemisphere. As a result of quantitative and statistical processing of a large array of digital data (more than 1000 thermal images in digital format), the amplitude and time parameters of thermal fields in the frozen area have been obtained.

It has been established that in the case of the low-temperature effect modes used [21], the ratio of the diameters of the necrosis area and the frozen area does not depend on the duration of exposure and is 0.63 ± 0.3 . During the thawing process, a long quasi-stable stage has been observed in the dynamics of the size and temperature of the frozen area. The authors have associated this effect with the processes of structural rearrangement of ice (recrystallization).

The temperature profiles along the line passing through the center of the ice spot at different times of thawing are shown in Fig. 12: the temperature distribution in 2 s (red curve), in 5 s (green curve), and in 90 s (blue curve) after the exposure to low temperature, which lasts 0.5 min. The blue curve corresponds to the quasi-stable stage. The inset shows a thermogram of a biological

object (rat) at a quasi-stable stage with the indicated position of the temperature profile.

The dynamics of the size and minimum temperature of the ice spot during natural thawing is shown in Fig. 13. Quasi-stable stages are observed in the dynamics of both parameters. More detailed results of these studies are published in [21].

CONCLUSION

1. In the case of burns, IRT has been successfully used both for early diagnosis of wound healing potential (in the acute period of a burn wound) and for the assessment of the effectiveness of burn wound therapy. Based on the obtained data, the prognostic method for assessing the category of healing potential based on the mean relative temperature of burn wound has been proposed. According to the results of the ROC analysis, the prognostic method has demonstrated “a good quality” (AUC = 0.79).

2. In the case of frostbite, IRT has been used to control the wound process in the reactive period (to clarify the stage of injury), as well as to evaluate the dynamics of granulation, epithelization, and scarring of wounds.

3. In the case of mechanical injuries and infections of the skin and soft tissues, IRT has been successfully used to identify blood and lymph circulation disorders, inflammatory and other general pathological processes and to assess the dynamics of wound healing.

4. The amplitude-time parameters of thermal fields on the surface of the skin exposed to low temperature have been measured. In the case of used low-temperature effect modes, the ratio of the necrosis area diameter to that of the frozen area is 0.63 ± 0.3 . In the course of thawing, a long quasi-stable stage of the size and temperature of the frozen area, which is possibly related to the structural rearrangement of the ice (recrystallization) has been recorded.

RESEARCH FUNDING

The research has been carried out with the support of the National Academy of Sciences

of Ukraine within the framework of grant 0121U108515 *Development of Thermal Imaging Equipment and Methods for Monitoring Temperature Fields of Human Skin During the Treatment of Soft Tissue Pathologies and Control of Low-Temperature Effects on Biological Tissues.*

ACKNOWLEDGEMENTS

The authors express their sincere thanks to combu-
stionologists of the Burn Treatment Center of the
Kharkiv city clinical hospital of emergency aid na-
med by Prof. O.I. Meshchaninov: Yu. P. Kolesnyk,
Y. G. Strilets, M. G. Nedviha, and nurses N. S. Pet-
rash. and Ya. A. Shchedrina for assistance in research.

REFERENCES

1. Venger, Ye. F., Dunaievsky, V. I., Kotovskiy, V. Yo., Bolgarska, S. V., Kyslyi, V. P., Tymofeyev, V. I., Orel, V. E., Nazar-
chuk, S. S. (2021). Infrared Thermography as an Effective Tool for Research and Industrial Application. *Sci. innov.*,
17(5), 20–33. <https://doi.org/10.15407/scine17.05.020>.
2. Diakides, N. A. (2007). *Medical Infrared Imaging*. New York: CRC Press.
3. Oliynyk, G. A., Kremen, V. A., Gryazin, A. E., Timchenko, E. K. (2018). Thermal Radiation and Thermal Imaging Studies
in Medicine. *Actual Problems of the Modern Medicine: Bulletin of Ukrainian Medical Stomatological Academy*, 18(2),
118–122. URL: https://www.pdmu.edu.ua/storage/magazines_prob_med_num/files/dSdh042ozCeksZIpqWE9ulRBF8ZvyzP9Htu9my0n.pdf (Last accessed: 19.04.2022).
4. International Classification of Diseases 11th Revision (ICD-11). URL: <https://icd.who.int/en> (Last accessed: 19.04.2022).
5. Classification of burn wounds by the depth of the lesion. Order of the Ministry of Health of Ukraine “On the system of
combustiological care in Ukraine” of 30.09.2013 No. 838 [in Ukrainian]. URL: <https://zakon.rada.gov.ua/laws/show/z2026-13> (Last accessed: 19.04.2022).
6. Carrière, M. E., de Haas, L. E. M., Pijpe, A., Meij-de Vries, A., Gardien, K. L. M., van Zuijlen, P. P. M., Jaspers, M. E. H.
(2020). Validity of thermography for measuring burn wound healing potential. *Wound Repair Regen*, 28(3), 347–354.
<https://doi.org/10.1111/wrr.12786>
7. Mariëlle, E. H., Jaspers, M., van Haasterecht, L., van Zuijlen, P., Mokkink, L. (2019). A systematic review on the quality
of measurement techniques for the assessment of burn wound depth or healing potential. *Burns*, 45(2), 261–281. <https://doi.org/10.1016/j.burns.2018.05.015>
8. Oliynyk, G. A., Kremen, V. O., Gryazin, O. Ye., Timchenko, O. K. (2017). Use of Thermography for the Purpose of Pro-
phylaxis of a Flap Bedsore. *Dermatovenereology. Cosmetology. Sexopathology*, (1–4), 56–59 [in Ukrainian] (Last ac-
cessed: 19.04.2022).
9. Grigorieva, T. G., Oliynyk, G. A., Tsogoev, A. A., Galata, A. I. (2010). Method of assessing the severity of cold injury.
Experimental and clinical medicine, 4, 133–137 [in Ukrainian].
10. Himashree, G., Dass, D., Singh, S., Lama, H., Chauhan, S. K. S., Bhaumik, G., Banerjee, P.K. (2007). Thermographic
evaluation of experimentally induced superficial and deep frostbite in rats. *Thermology international*, 17(2), 51–58. URL:
https://www.researchgate.net/publication/285964197_Thermographic_evaluation_of_experimentally_induced_superficial_and_deep_frostbite_in_rats (Last accessed: 19.04.2022).
11. Montalto, M., Davies, F., Marijanovic, N., Meads, A. (2013). Skin surface temperature: a possible new outcome measure
for skin and soft tissue infection. *Australian Family Physician*, 42(9), 653–657. URL: <https://www.racgp.org.au/afp/2013/september/skin-surface-temperature/> (Last accessed: 19.04.2022).
12. Abramovits, W., Graham, G., Har-Shai, Ya., Strumia, R. (2016). *Dermatological Cryosurgery and Cryotherapy*. London:
Springer. <https://doi.org/10.1007/978-1-4471-6765-5>
13. Pasquali, P. (2015). *Cryosurgery. A Practical Manual*. Berlin, Heidelberg: Springer. <https://doi.org/10.1007/978-3-662-43939-5>
14. Chyzh, M. O., Belochkina, I. V., Hladkykh, F. V. (2021). Cryosurgery and physical medicine in treatment of cancer. *Ukrainian journal of radiology and oncology*, 29(2), 127–149 [in Ukrainian]. <https://doi.org/10.46879/ukroj.2.2021.127-149>
15. Overduin, C. G., Fütterer, J. J., Scheenen, T. W. J. (2016). 3D MR thermometry of frozen tissue: Feasibility and accuracy
during cryoablation at 3T. *J. Magn. Reson. Imaging*, 44(6), 1572–1579. <https://doi.org/10.1002/jmri.25301>
16. Gordiyenko, E. Yu., Glushchuk, N. I., Pushkar, Yu. Ya., Fomenko, Yu. V., Shustakova, G. V. (2012). A Multi-element
Thermal Imaging System Based on an Uncooled Bolometric Array. *Instrum. Exp. Tech.*, 55(4), 494–497. URL: <https://link.springer.com/article/10.1134/S0020441212030050> (Last accessed: 19.04.2022).

17. Cohen, E. E. W., Ahmed, O., Kocherginsky, M., Shustakova, G., Kistner-Griffin, E., Salama, J. K., Yefremenko, V., Novosad, V. (2013). Study of Functional Infrared Imaging for Early Detection of Mucositis in Locally Advanced Head and Neck Cancer Treated With Chemoradiotherapy. *Oral Oncology*, 49(10), 1025–1031. <https://doi.org/10.1016/j.oraloncology.2013.07.009>
18. Glantz, C. (1998). *Biomedical statistics*. Moscow: Practice [in Russian].
19. Rummyantsev, P. O., Saenko, U. V., Rummyantseva, U. V. (2009). Statistical methods for the analyses in clinical practice. Part 1. Univariate statistical analysis. *Problems of Endocrinology*, 55(5), 48–55 [in Russian]. <https://doi.org/10.14341/probl200955548-55>
20. On the protection of animals used for scientific purposes: Directive 2010/63/EU of the European Parliament and of the Council of 22 September 2010. *Official Journal of European Union*. 2010. L.276/33-L.276/79.
21. Kovalov, G. O., Shustakova, G. V., Gordiyenko, E. Yu., Fomenko, Yu. V., Glushchuk, M. I. (2021). Infrared thermal imaging controls freezing and warming in skin cryoablation. *Cryobiology*, 103, 32–38. <https://doi.org/10.1016/j.cryobiol.2021.09.014>
22. Yefremenko, V., Gordiyenko, E., Shustakova, G., Fomenko, Yu., Datesman, A., Wang G., ... Novosad, V. (2009). A Broad-band imaging system for research applications. *Rev. Sci. Instrum.*, 80(5), 056104. <https://doi.org/10.1063/1.3124796>
23. Dokhov, M. A., Tikhomirova, A. A., Vaulin, G. F. (2004). *Nonparametric criterions in the program "STATISTICA". Teaching methodical manual*. St. Petersburg: St. Petersburg State Pediatric Medical University [in Russian].
24. Ivanitskii, G. R., Deev, A. A., Kreteva, I. B., Khizhnyak, E. P., Khizhnyak, L. N. (2004). Characteristics of Temperature Distributions around the Eyes. *Doklady Biological Sciences*, 398, 367–372. <https://doi.org/10.1023/B:DOBS.0000046658.90357.2d>
25. Kovalov, G., Gordiyenko, E., Fomenko, Yu., Shustakova, G., Kiporenko, P., Olefirenko, O. (2020). Dynamics of Freezing and Warming of Soft Tissues with Short-Term Effect on Skin with Cryoapplicator. *Probl. Cryobiol. Cryomed.*, 30(4), 359–368. <https://doi.org/10.15407/cryo30.04.359>
26. Korpan, N. N., Chefranov, S. G. (2020). Estimation of the stable frozen zone volume and the extent of contrast for a therapeutic substance. *PLoS ONE*, 15, e0238929. <https://doi.org/10.1371/journal.pone.0238929>

Received 18.02.2022

Revised 12.06.2022

Accepted 20.06.2022

М. І. Глушук¹ (<https://orcid.org/0000-0001-7723-638>),
Г. В. Шустакова¹ (<https://orcid.org/0000-0002-8737-0359>),
Е. Ю. Гордиєнко¹ (<https://orcid.org/0000-0002-8692-8605>),
Ю. В. Фоменко¹ (<https://orcid.org/0000-0003-3108-8431>),
Г. А. Олійник² (<https://orcid.org/0000-0002-7445-553X>),
В. В. Дворцевий² (<https://orcid.org/0000-0003-3632-9361>),
В. О. Кремень² (<https://orcid.org/0000-0002-2946-9430>),
Г. О. Ковальов³ (<https://orcid.org/0000-0002-5714-6698>),
М. О. Чиж³ (<https://orcid.org/0000-0003-0085-296X>),
К. Г. Сурпул⁴ (<https://orcid.org/0000-0003-2540-9147>)

¹ Фізико-технічний інститут низьких температур ім. Б.І. Веркіна
Національної академії наук України,
просп. Науки, 47, Харків, 61103, Україна,
+380 57 340 2223, ilt@ilt.kharkov.ua

² Харківська медична академія післядипломної освіти,
вул. Амосова, 58, Харків, 61176, Україна,
+380 57 711 3556, office@med.edu.ua

³ Інститут проблем кріобіології і кріомедицини
Національної академії наук України,
вул. Переяславська, 23, Харків, 61016, Україна,
+380 57 373 4143, cyo.ua@gmail.com

⁴ ДУ Харківський Інститут дерматології та венерології
Національної академії медичних наук України,
вул. Чернишевська, 7/9, Харків, 61057, Україна,
+380 57 706 3200, idvnamnu@ukr.net

ТЕРМОГРАФІЧНЕ ДОСЛІДЖЕННЯ УРАЖЕННЯ М'ЯКИХ ТКАНИН ЛЮДИНИ ТА НИЗЬКОТЕМПЕРАТУРНОГО ВПЛИВУ НА БІОЛОГІЧНІ ТКАНИНИ *in vivo*

Вступ. Інфрачервона термографія на сьогодні використовується у клінічній практиці лише як додатковий метод через недостатні знання про патофізіологічні основи теплових зображень.

Проблематика. Основним методом діагностики тяжкості ураження м'яких тканин є візуальна оцінка лікаря. Наразі не існує неінвазивного методу контролю динаміки температури в замороженій зоні в реальному часі кріовпливу.

Мета. Оцінити можливість термографії для кількісної діагностики тяжкості ураження м'яких тканин при термічних та інших ушкодженнях, неінвазивного контролю стану рани під час лікування, поточного контролю динаміки теплового поля в замороженій зоні протягом кріовпливу на шкіру.

Матеріали й методи. У дослідженні взяли участь 80 пацієнтів з ураженням м'яких тканин, яких обстежували оригінальним матричним термографом протягом періоду лікування. Контроль кріовпливу на м'які тканини 30 експериментальних тварин проводили за допомогою іншого оригінального термографу, розробленого для вимірювання низькотемпературних теплових полів.

Результати. Запропоновано прогностичний метод оцінки категорії потенціалу загоєння опікової рани за середнім значенням її відносної температури. Для оцінки прогностичної якості методу застосовано ROC-аналіз (Receiver Operating Characteristic): числовий показник площі під кривою чутливості та специфічності методу склав 0.79, що відповідає хорошій якості прогностичного методу. Встановлено, що співвідношення діаметрів зони первинного некрозу та замороженої зони становить $0,63 \pm 0,3$ при використаних параметрах низькотемпературного впливу. Під час відтавання спостерігалася тривала квазістабільна стадія розмірів і температур замороженої зони.

Висновки. Показано можливість успішного використання термографії як для моніторингу уражень м'яких тканин на всіх етапах лікування, зокрема як для кількісної оцінки потенціалу загоєння опікових ран, так і для інтраопераційного контролю параметрів замороженої зони під час кріодеструкції тканин.

Ключові слова: термографія, м'які тканини, опіки, обмороження, низькотемпературний вплив.